



## PATIENT

Mana Peters

## SPECIES

Canine

## BREED

Pomeranian

## SEX

FS

## AGE

8 y

## WEIGHT

5.3 kg

## INTERPRETED BY

Keith Blass, DVM, MS,  
DACVIM (Cardiology)

## IMAGING PERFORMED BY

Dr. Brian Barnes

## HOSPITAL NAME

Westview VH

## REFERRING VET

Dr. Barnes

## INVOICE

## DATE

12/9/25

## PRESENTING CLINICAL SIGNS

Grade 3/6 left basilar murmur.

## ECHOCARDIOGRAPHIC FINDINGS

2D, M-mode, and Doppler study.

Left atrial size is normal. The mitral valve leaflets are mildly thickened and exhibit mild systolic prolapse. A moderate jet of mitral regurgitation is present. Left ventricular dimensions are normal. Left ventricular systolic function is hyperdynamic. The aorta and aortic valve are normal. Right atrial and right ventricular dimensions are normal. The tricuspid valve leaflets are mildly thickened, and a mild jet of tricuspid regurgitation is present. TR velocity does not suggest the presence of pulmonary hypertension. The pulmonary artery and pulmonic valve appear normal, though trace pulmonic insufficiency is present. No shunting lesions are visualized. No heartworms are visualized. No pericardial effusion or cardiac masses are seen.

ECG during echo: Sinus rhythm

LA - 23.4 mm  
LVIDd - 23.6 mm  
LVIDs - 12.9 mm  
FS - 45.3%  
RA - 13.7 mm  
LVOT - 1.39 m/s  
RVOT - 0.93 m/s  
TR - 1.14 m/s

## ASSESSMENT/RECOMMENDATIONS

Degenerative mitral and tricuspid valve disease - stage B1

This examination demonstrates regurgitation of blood across Mana's mitral and tricuspid valves resulting from degenerative valve disease. The hemodynamic effects of the regurgitations appear to be mild at present, as Mana does not have secondary dilation of any of her cardiac chambers, and her ventricular systolic function is well-preserved. As such, Mana's current risk for the development of clinical signs secondary to her valvular diseases, such as coughing, exercise intolerance, syncope, labored breathing, and abdominal distension, appears to be low.

No therapy is recommended at this stage of Mana's valvular diseases.

A recheck echocardiogram is recommended in 6 months to monitor for disease progression.



### PATIENT

Mana Peters

### SPECIES

Canine

### BREED

Pomeranian

### SEX

FS

### AGE

8 y

### WEIGHT

5.3 kg

### INTERPRETED BY

Keith Blass, DVM, MS,  
DACVIM (Cardiology)

### IMAGING PERFORMED BY

Dr. Brian Barnes

### HOSPITAL NAME

Westview VH

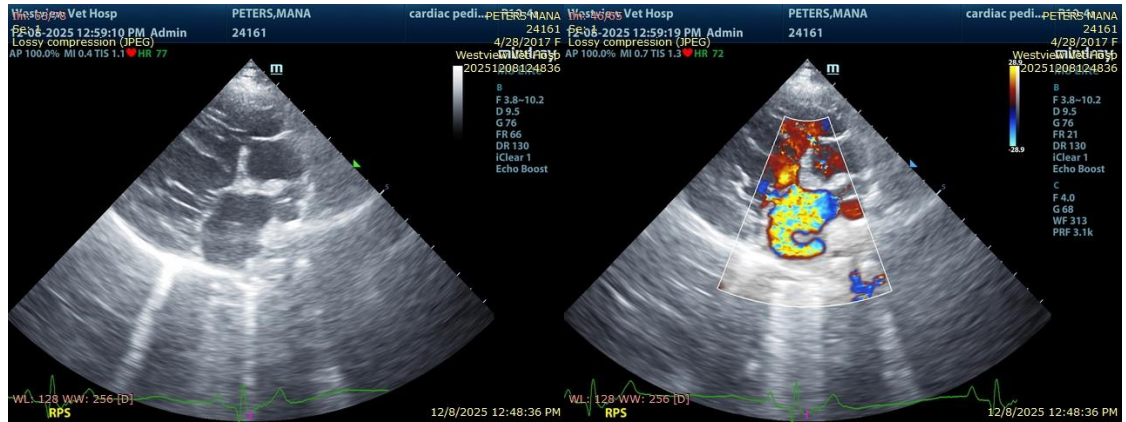
### REFERRING VET

Dr. Barnes

### INVOICE

### DATE

12/9/25



The information and recommendations provided are based on the images presented by the referring veterinarian/sonographer. No evaluation can be communicated regarding pathology that was not visible in the image/video clips provided.

Thank you for this referral. If the clinical or image interpretation does not parallel your findings or if I can be of any further assistance please contact me.

Keith Blass, DVM, MS, DACVIM (Cardiology)

[info@SonoPath.com](mailto:info@SonoPath.com)